

# **MUMMIFICATION, MACERATION AND PYOMETRA IN BOVINE**

**Dr. S. N. Shukla**

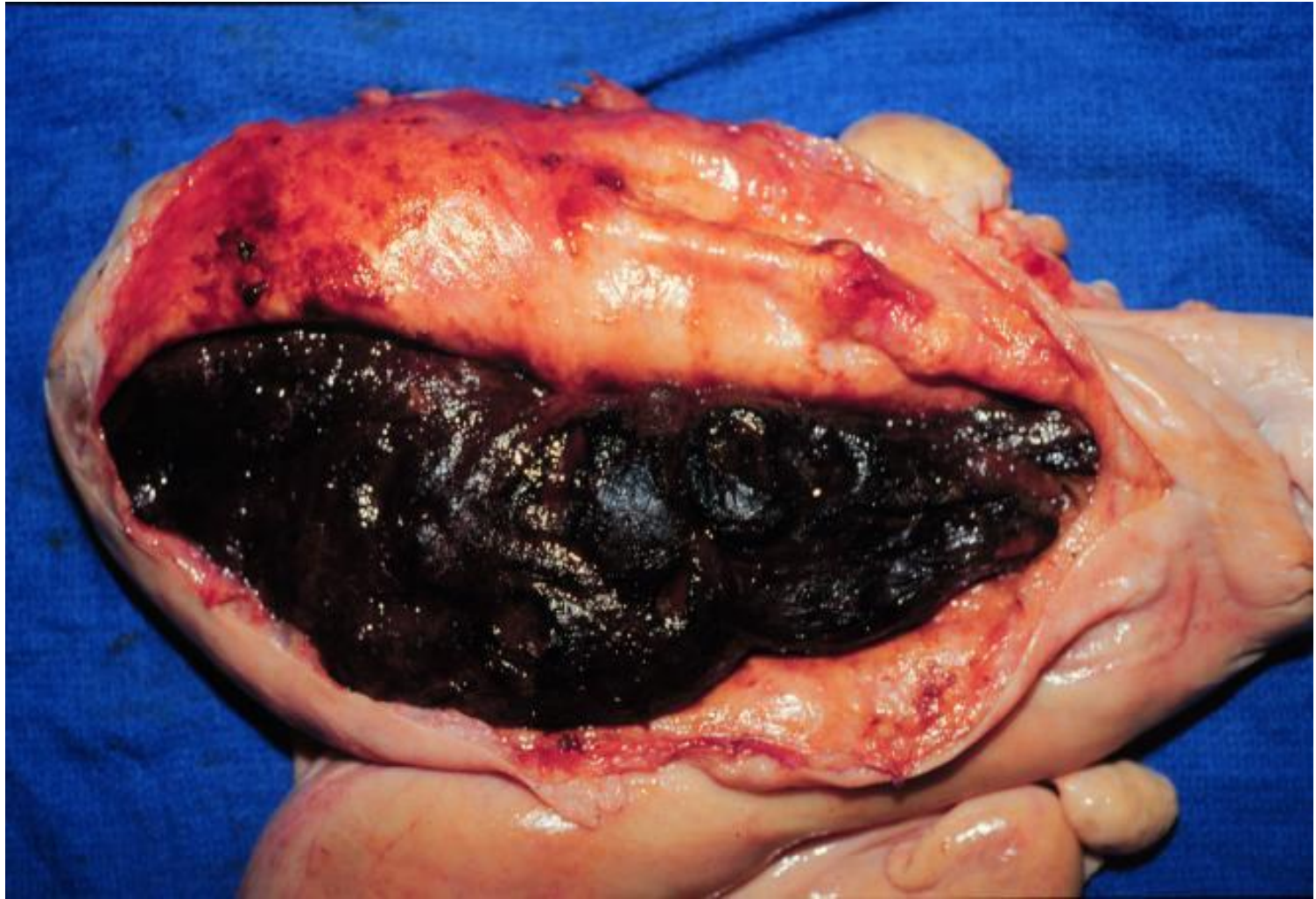
**Associate Professor**

**Department of Veterinary Gynaecology & Obstetrics,  
CVSC. & AH, NDVSU, Jabalpur**

# **MUMMIFICATION, MACERATION AND PYOMETRA IN BOVINE**

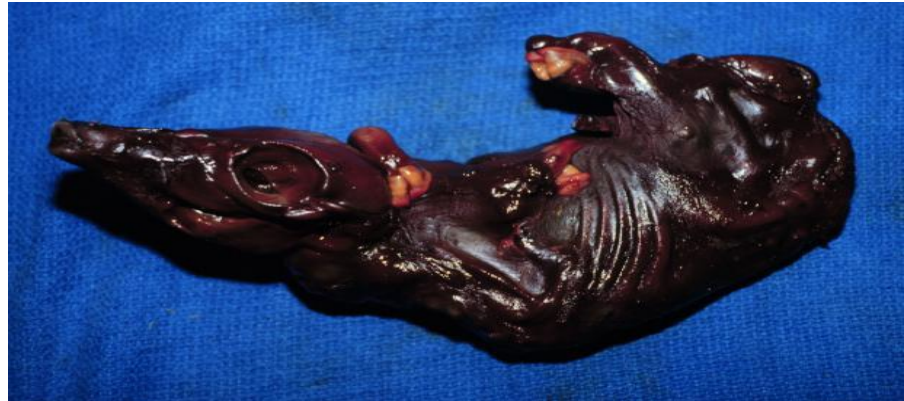# FETAL MUMMIFICATION

Fetal membranes becomes shrivelled & dried, fluids of allantois, amnion & fetus are resorbed and uterus contracts on fetus and moulds it into a dry, contorted mass leads to death of fetus at middle and last trimester of gestation



## HAEMATIC TYPE MUMMIFICATION IN BOVINE

- Semifluid viscous,reddish brown coloured adhesive substance of haematogenous origin accumlate between uterus and chorion, imparting a reddish brown colour to the fetus and fetal membrane.



- If the condition is undiagnosed mummified fetus will remain in the uterus beyond the normal gestation period.
- Fetal Mummification associated with a persistent Corpus Luteum when the parturition abortion mechanism fail to occur.

## DIAGNOSIS

❖ By Rectal Exploration when no sign of approaching parturition are seen.

### ❖ **MOST STRIKING CLINICAL FEATURES ARE**

- Pregnant uterus relatively small , lacks fluid and contained irregular, inert fetal mass.
- No Cotyledons
- Uterine Artery is small and without Fremitus.
- Ovary containing Corpus Luteum is palpable.

# CAUSES OF FETAL MUMMIFICATION

1. Torsion or compression of umbilical cord
2. Genetic Factor
  - [a] Inherited Endocrine Defects
  - [b] Autosomal Recessive Genes
3. Torsion of uterus

All Mummified fetus and uteri when examined and cultured are sterile.

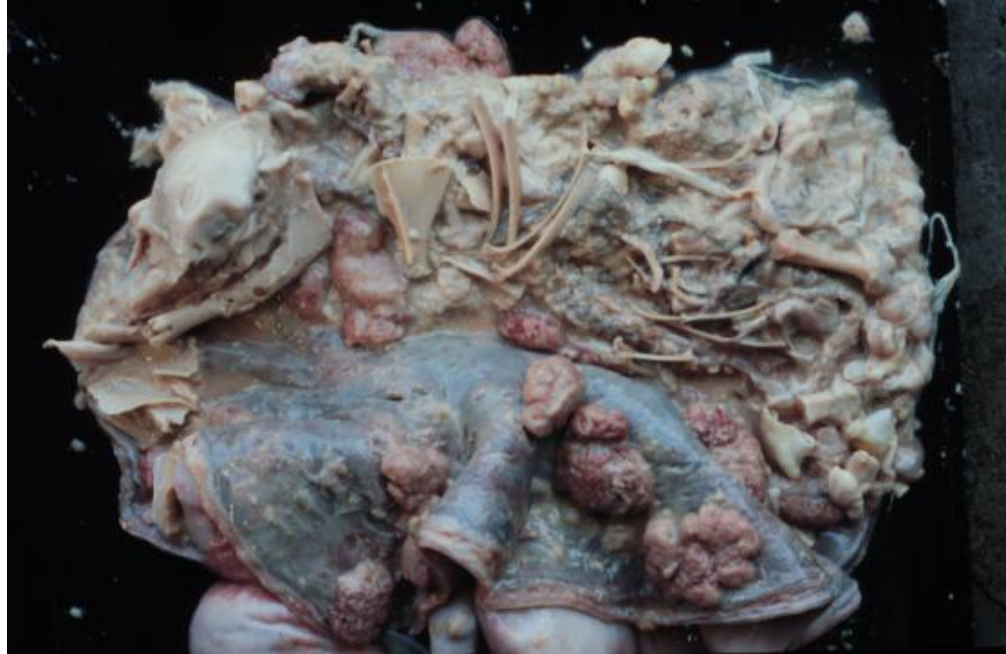# TREATMENT

- Rational approach is to initiate parturition by using PGF<sub>2</sub>α 25mg intramuscular within 24- 48 hrs cervix dilate and remove mummified fetus.
- STILLBOESTROL Inj. May cause cystic degeneration of ovary and subsequent sterility.
- Extrusion of Corpus Luteum manually may do irreparable damage to ovary as it is firmly embedded in ovary.



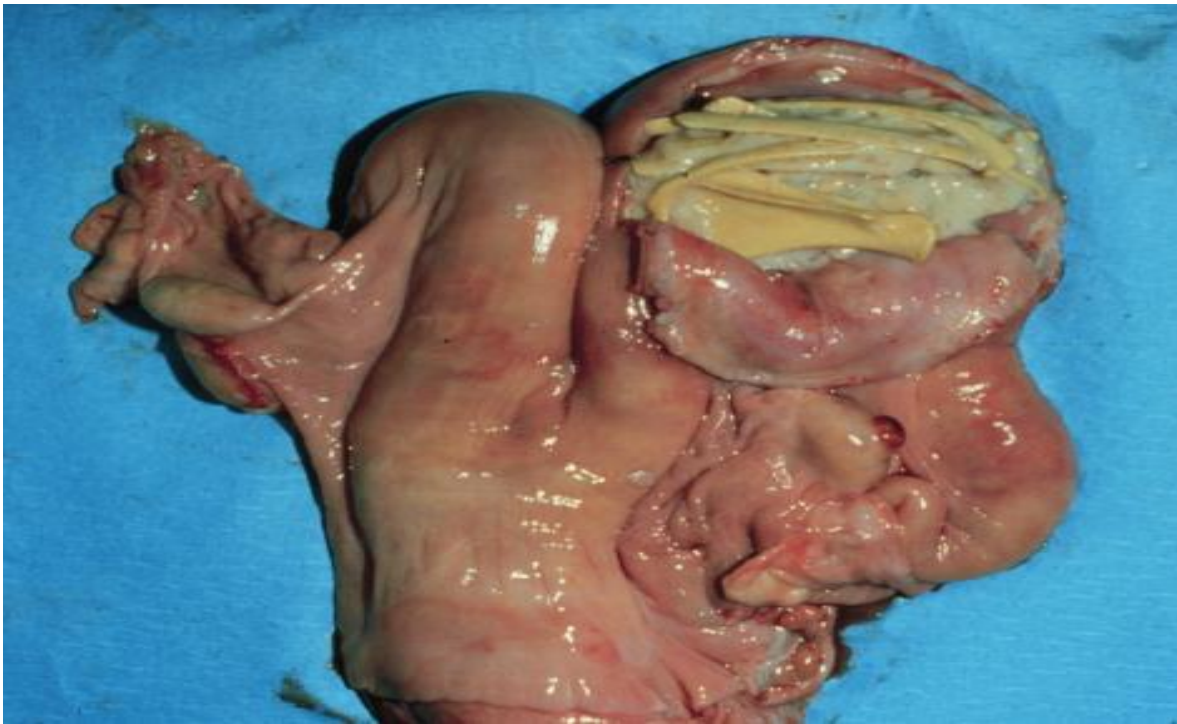
# FETAL MACERATION

- Failure of an aborting fetus to be expelled due to uterine inertia in a dilated cervix.
- Fetus undergoes a gradual bacterial digestion in the uterine fluid by a process described as MACERATION.
- Maceration may occur at any stage of gestation.



## CAUSES OF MACERATION

- Uterine Inertia, Improper dilation of cervix.
- Conditions like Trichomoniasis and Vibrosis.
- Maceration associated with Uterine Torsion during Gestation.



## DIAGNOSIS OF FETAL MACERTION

- Intermittent straining with a foul,reddish grey vulval discharge.
- On per rectal examination reveal a distened,swollen fetus where fetal bones floating in pus or crepitating against each other.
- Uterine wall will be thick and heavy with a large and hard cervix.

## PROGNOSIS

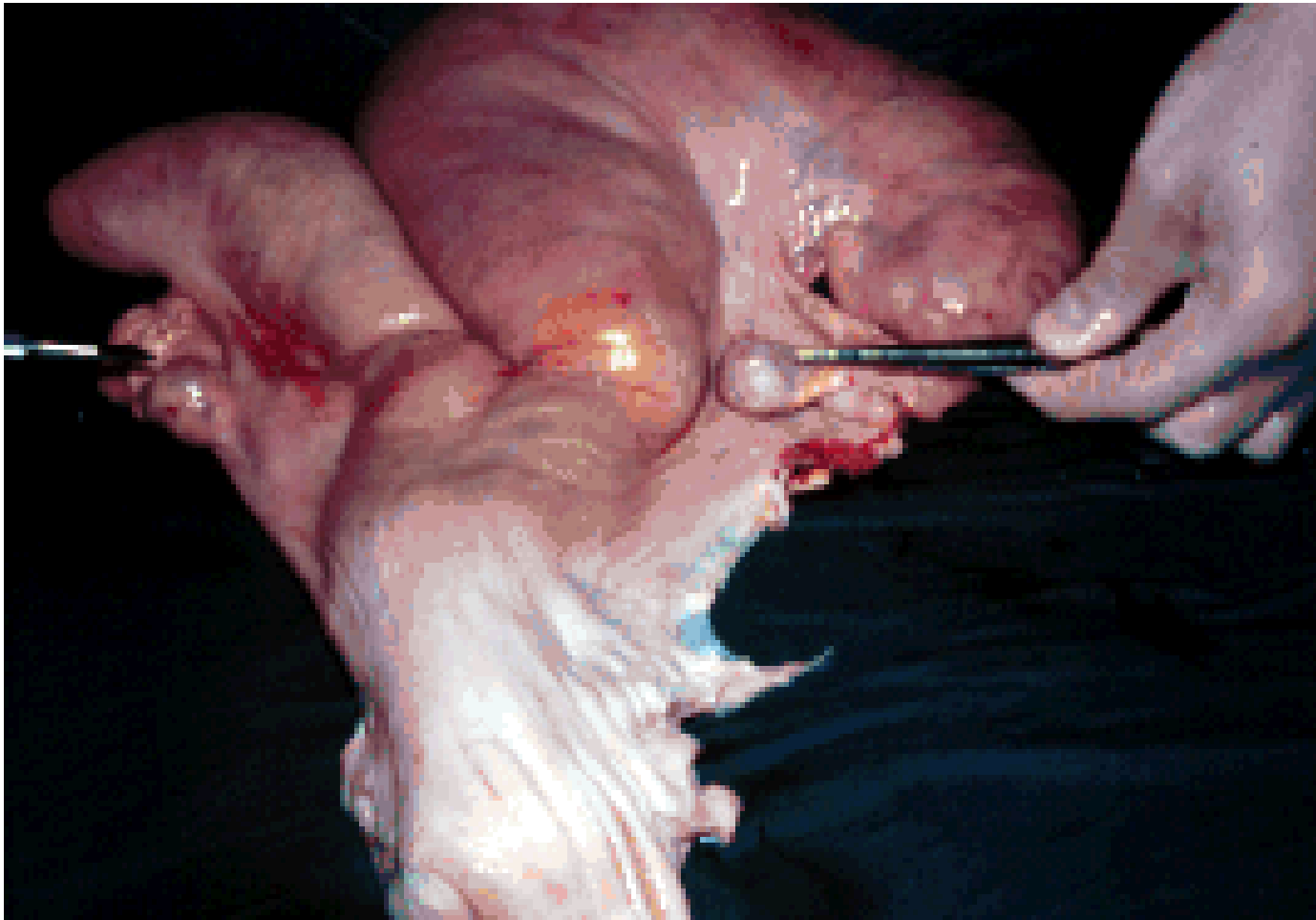
- Grave and future Breeding Life is Questionable.
- Longer the condition existed the greater damage to endometrium and poorer the prognosis.

# TREATMENT

- Estradiol 8-10 mg
- Diethylstilbestrol 80-100 mg result cervical relaxation and extraction of fetus.
- With supportive antibiotic therapy can save the reproductive status of dam at early condition.

## PYOMETRA IN BOVINE

- A Progressive accumulalation of pus in the uterus with a persistent CorpusLuteum or rarely a Luteal Cyst.
- Volume of 1 to 20 liter pus leads to distension of uterus.



# ETIOLOGY & PREDISPOSING FACTOR

- As a sequel to chronic Endometritis & Embryonic Death.
- Uterus cease to produce Endogenous Leuteolysin.
- *Trichomonas fetus* and *Corynebacterium pyogenes* infection.

# DIAGNOSIS

- No sign of ill health.
- Absence of Cyclical activity and intermittent vaginal discharge.
- On Rectal Exploration uterine horn are enlarged and distended.

# TREATMENT

- PGF2 alpha 25 mg intramuscular result regression of Corpus Luteum, dilation of cervix and expulsion of purulent fluid.
- Antibiotic not given intrauterine as no action on pus.
- Lugol's iodine used alternate day 50 ml intra uterine 0.5-1% along with broad-spectrum antibiotics like Gentamicin 2-4 ml.